

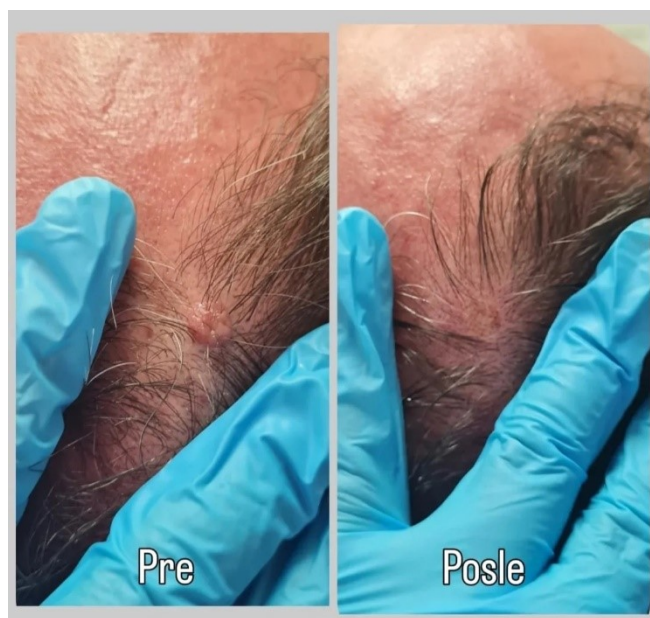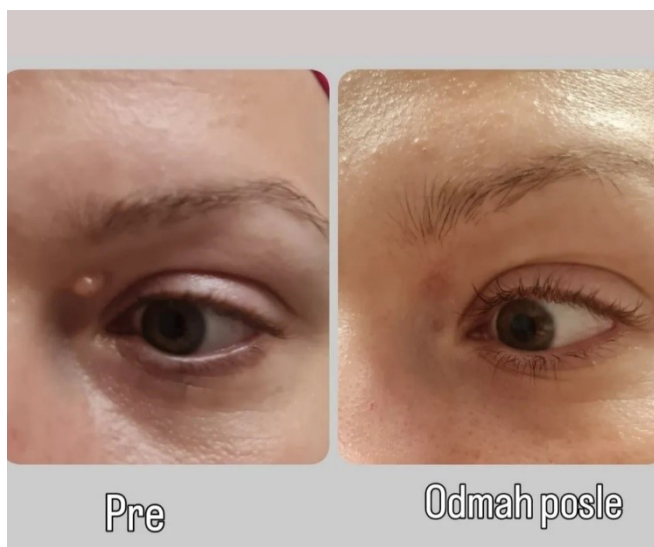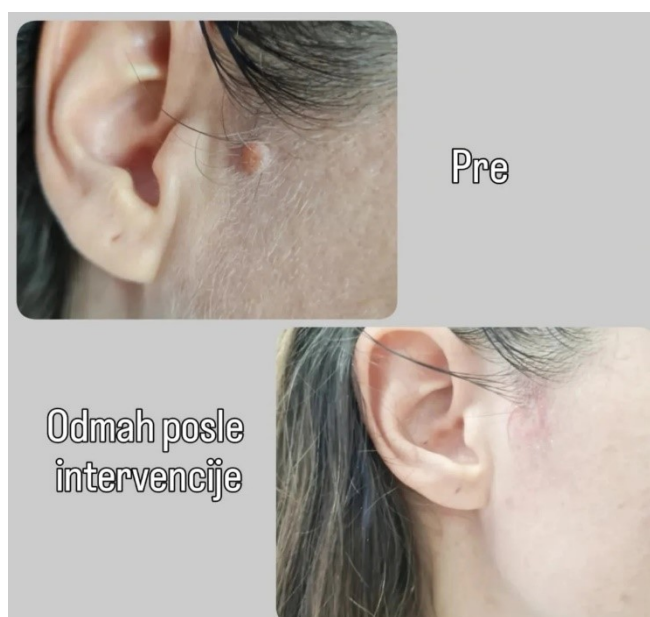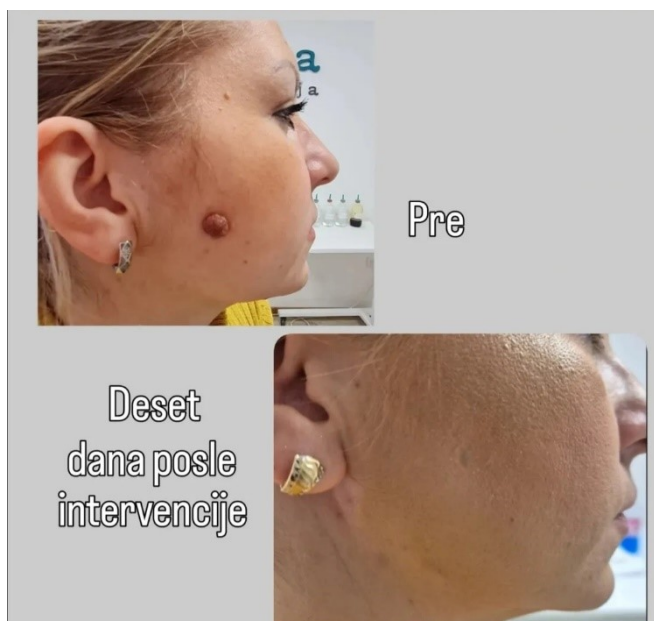
CASE REPORT

Radiofrequent electrosurgery - Removal of benign changes on the skin

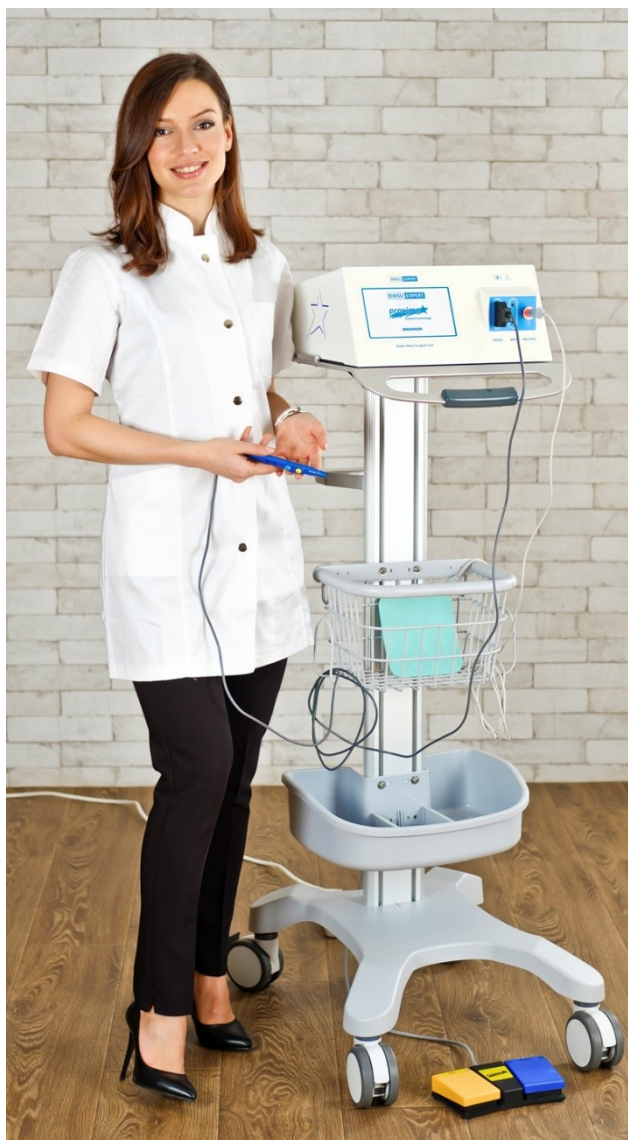Report of Dr Nenad Ivančević, surgeon, Clinic Invita, Belgrade

Device: RWSU Expert

Aesthetic procedure done under local anesthesia on female and male with photo documentation before and after intervention.



Doctors comments : It was observed that here was almost no scarring or tissue discoloration on post-op check, and healing process resulted in almost no visual recognition of performed intervention. Great patient satisfaction achieved.



Device used – RWSU Expert