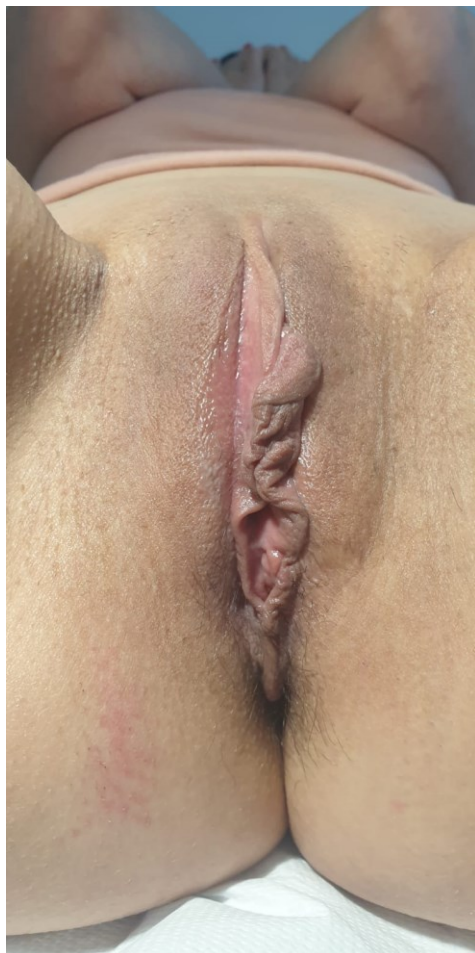


CASE REPORT

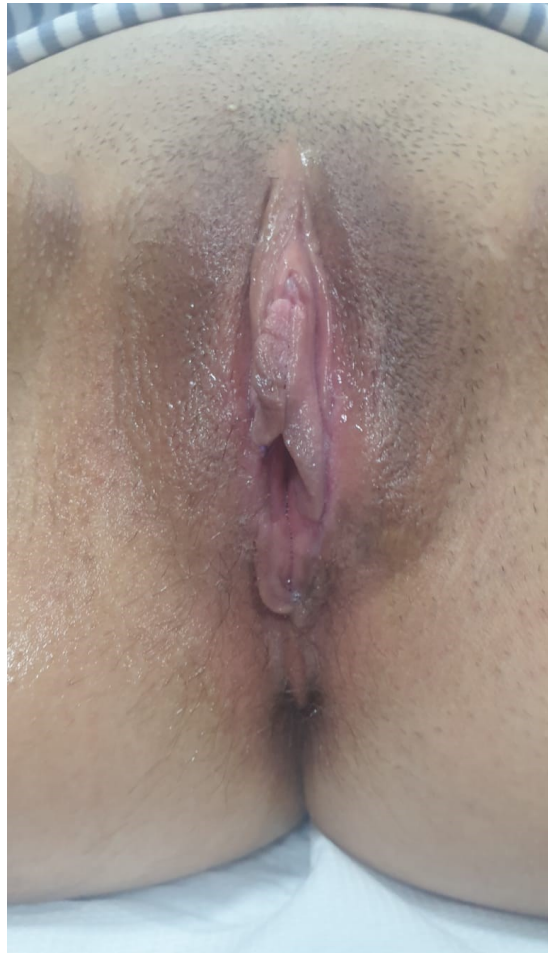
Radiofrequent electrosurgery for Labiaplasty  
Courtesy of Mrs Violeta Škorić, MD, Urologist, Serbia  
Device: RWSU 70

Aesthetic procedure done under local anesthesia on a 45yo female, with photo documentation before and 20 days post-op.

Before



20 days post-op



Doctor's comments: It was observed that there was almost no scarring or tissue discoloration on post-op check, and healing process resulted in almost no visual recognition of performed intervention. Great patient satisfaction achieved.

Device used – RWSU 70:

